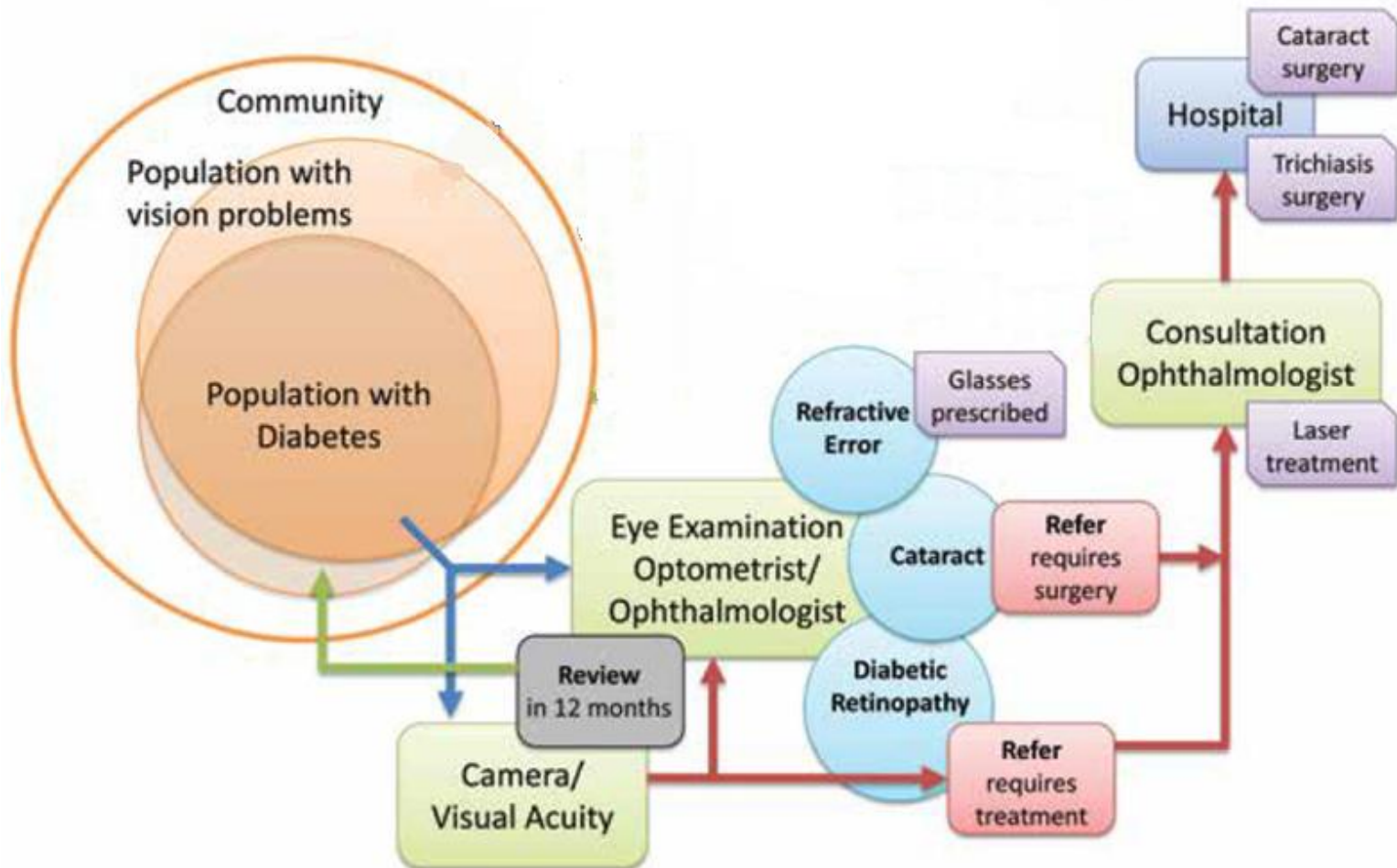
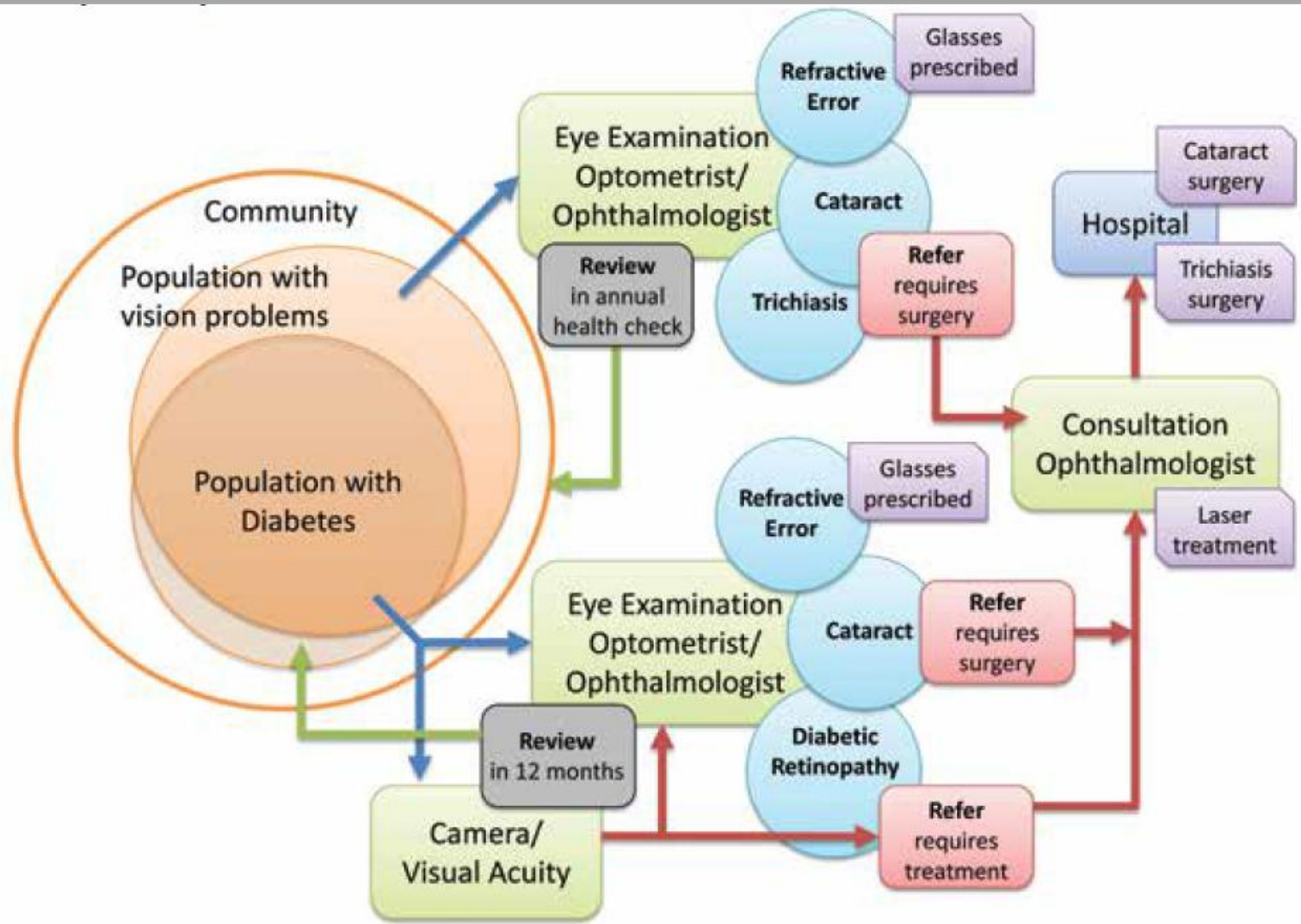


Online Self-Directed Diabetic Retinopathy Grading Course

Hugh R Taylor AC
Harold Mitchell Chair of Indigenous Eye Health
Melbourne School of Population Health
The University of Melbourne








ICO Activities

- Guidelines for Diabetic Retinopathy
 - Covers screening, ophthalmic examination, management including treatment and assessment indicators
 - Draft completed September 2013
 - To be circulated to Retinal Society Members October 2013
 - Finalised November 2013
 - Released December 2013
- Education Process - ongoing
 - Information to be included in spectrum of ICO educational activities including curricula, exams, fellowships, teach the teachers, online learning, and WOC

Overview

- ◆ Blindness from diabetic retinopathy is almost entirely preventable with regular eye examinations and timely laser surgery.
- ◆ We develop an online self-directed diabetic retinopathy grading course, for use by general practitioners and other health professionals, using retinal photography.
- ◆ The course covers:
 - Epidemiology of diabetic retinopathy
 - Pathology that makes up diabetic retinopathy
 - Stages of diabetic retinopathy
 - Referrals



Epidemiology of Diabetic Retinopathy

The section on the epidemiology of diabetic retinopathy cover key questions including:

- ◆ What is diabetic retinopathy?
- ◆ Who is at risk of developing diabetic retinopathy?
- ◆ How effective is current treatment at preventing blindness?
- ◆ Is screening for diabetic retinopathy important?
- ◆ What is the time frame for screening for retinopathy?

How to screening for diabetic retinopathy

The section on how to screen for diabetic retinopathy is divided into two parts:

Distant visual acuity

- ◆ Equipment
- ◆ How to record visual acuity
- ◆ Visual acuity test

Grading diabetic retinopathy, macular oedema and referral plans

- ◆ Review of the pathology that makes up retinopathy
- ◆ Review of the stages of retinopathy
- ◆ Review macular oedema
- ◆ Referral plans

Visual Acuity

How to Screen for Diabetic Retinopathy

DISTANT VISUAL ACUITY

- >> Equipment
- >> How to record visual acuity
- >> Visual acuity test
- >> Quiz Questions #2

EYE EXAMINATION & REFERRAL

Review Stages of Diabetic Retinopathy

PART 1

PART 2

PART 3


PART 4

COMPETENCY BASED EXAMINATION

Distant Visual Acuity

Equipment

Distant Visual Acuity chart: Snellen chart (letters) or an Illiterate E or Lea Chart (6 meter or 3 meter).



Put the eye chart against a wall, measure and mark a spot on the floor 6 meters away from a 6 meter chart or 3 meters away from a 3 meter chart (20 feet). The room should be well illuminated.

How to record visual acuity

The first number is always 6 – the testing distance. This also applies to 3 meter charts as the size and distance away are proportionally the same. The last number is the smallest line the patient can read off the chart. Record eye, left and right.

If the patient normally wears glasses for distant vision, they should wear the glasses for the examination.

Grading diabetic retinopathy and referral plans

Diabetic Retinopathy

OVERVIEW

EPIDEMIOLOGY

How to Screen for Diabetic Retinopathy

DISTANT VISUAL ACUITY

EYE EXAMINATION & REFERRAL

- » Diabetic retinopathy defined
- » Stages of diabetic retinopathy
- » Criteria for urgent referral

Review Stages of Diabetic Retinopathy

PART 1

PART 2

PART 3

PART 4

COMPETENCY BASED EXAMINATION

[Home](#) | [Diabetic Retinopathy](#) | Eye Examination & Referral

Eye Examination & Referral

In this step we will provide a general overview of the stages of diabetic retinopathy and diabetic macular oedema and outline the referral plan for each stage. We will review the pathology of diabetic retinopathy and diabetic macular oedema, and provide practice sessions for you to become competent at screening and providing appropriate referrals.

Diabetic retinopathy defined

Diabetic retinopathy is defined as the presence of retinal microvascular lesions in an individual with diabetes. Microaneurysms, haemorrhages, soft exudates, hard exudates, intraretinal microvascular abnormalities, venous beading, new vessels and fibrous tissue comprise the clinical features of diabetic retinopathy. However, no individual lesion is specific for diabetes, as each may occur in other disease processes such as hypertension. It is the pattern and evolution of the lesions that characterises diabetic retinopathy. (*Guidelines for the management of diabetic retinopathy, page 36*)

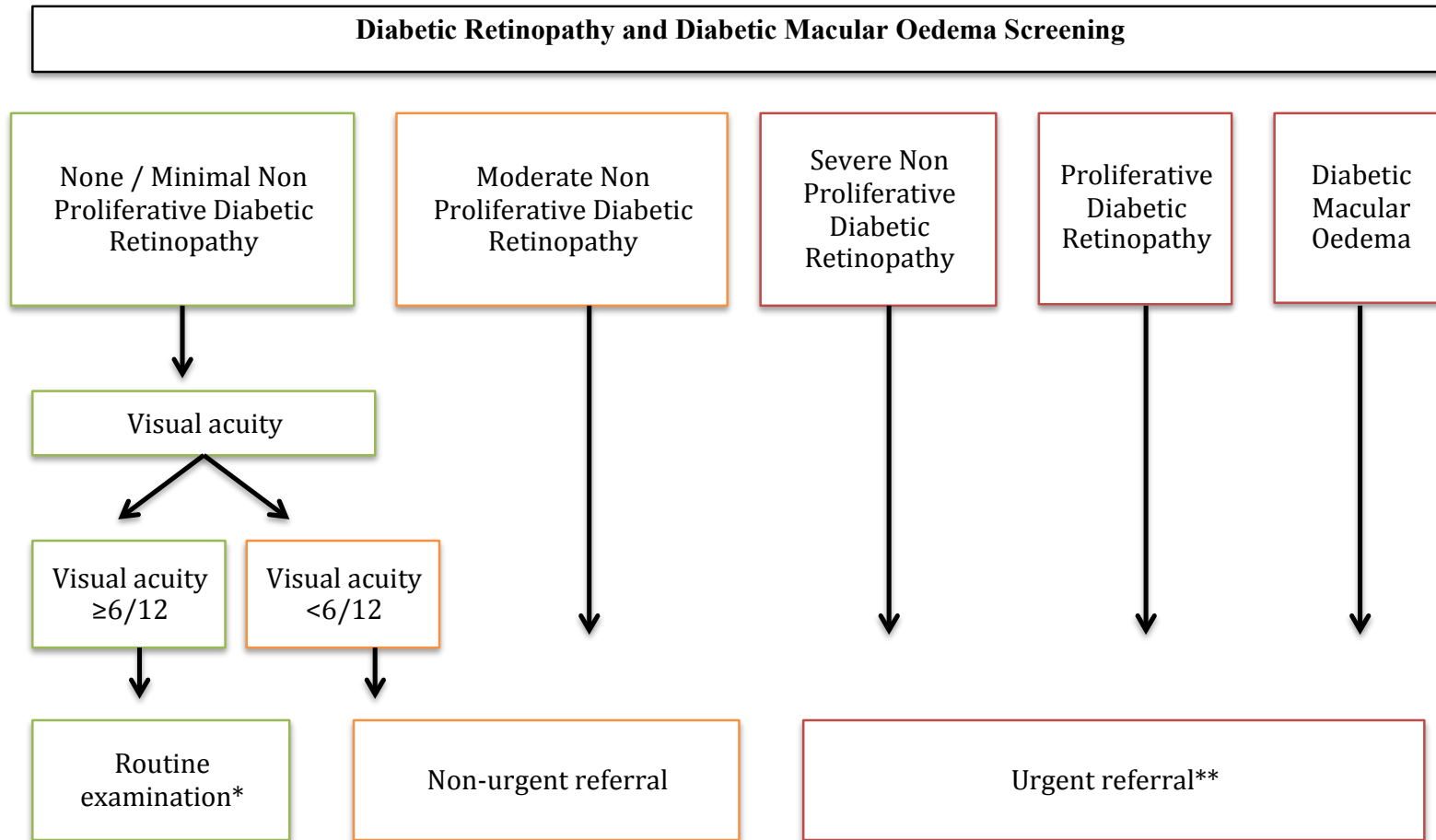
Stages of diabetic retinopathy

Diabetic retinopathy is made up of stages, normal and minimal non-proliferative diabetic retinopathy, moderate non-proliferative diabetic retinopathy, severe non-proliferative diabetic retinopathy and proliferative diabetic retinopathy. It also includes assessment of diabetic macular oedema (suspected / absent). Table 1 shows the International Clinical Diabetic Retinopathy and Diabetic Macular Oedema Disease Severity Scale. The retinal pathology used to classify each stage of diabetic retinopathy and macular oedema are shown.

Criteria for urgent referral

The main objective of diabetic retinopathy screening is to prevent blindness from sight threatening retinopathy. Patients with any level of diabetic macular oedema, severe non-proliferative diabetic retinopathy, any proliferative retinopathy or vitreous haemorrhage require urgent referral from an ophthalmologist experienced in diabetic retinopathy management. A non-urgent referral is also needed if there is any loss of vision (<6/12), or if the retina cannot be examined properly. Early diabetic macular oedema that may not be obvious on a retinal photograph, may cause a reduction in visual acuity as can other eye conditions such as a change in refractive error or cataract. Therefore any case of poor vision (<6/12) should initiate a referral.

Grading diabetic retinopathy and referral plans



*Routine examination - Indigenous people with diabetes should undergo an eye examination at diagnosis and annually thereafter and at diagnosis and every two years for non-Indigenous people. **NHMRC defines urgent as 'see within four weeks'.

Overview of the stages of diabetic retinopathy

Diabetic Retinopathy

OVERVIEW

EPIDEMIOLOGY

How to Screen for Diabetic Retinopathy

DISTANT VISUAL ACUITY

EYE EXAMINATION & REFERRAL

Review Stages of Diabetic Retinopathy

PART 1

- » Normal Retina
- » Artifacts
- » Poor quality images
- » Minimal non-proliferative diabetic retinopathy / microaneurysms
- » Quiz Questions #3

PART 2

[Home](#) | [Diabetic Retinopathy](#) | Review the Stages of Diabetic Retinopathy

Review the Stages of Diabetic Retinopathy

Normal retina

This is what a normal retina looks like.

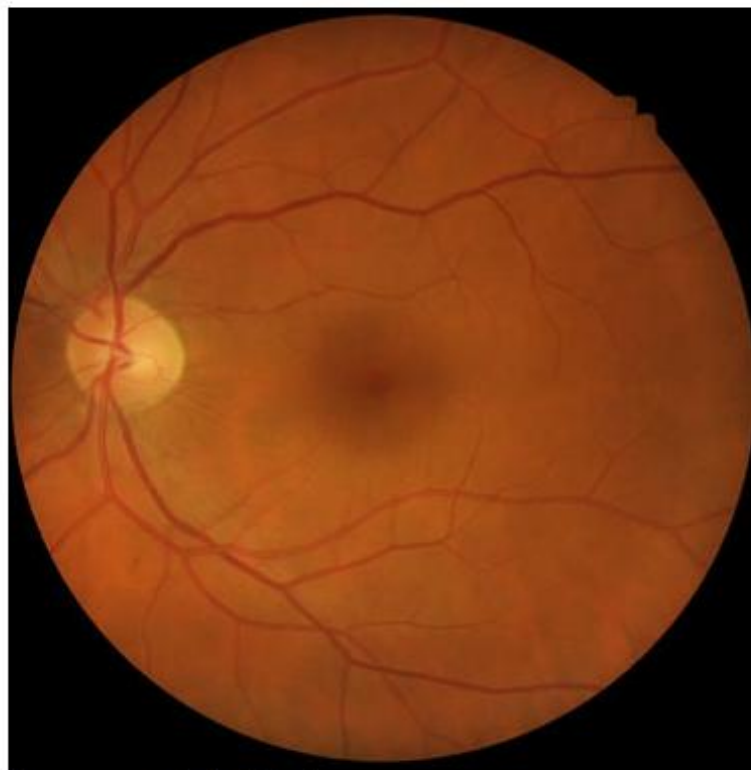

Image example: light fundus

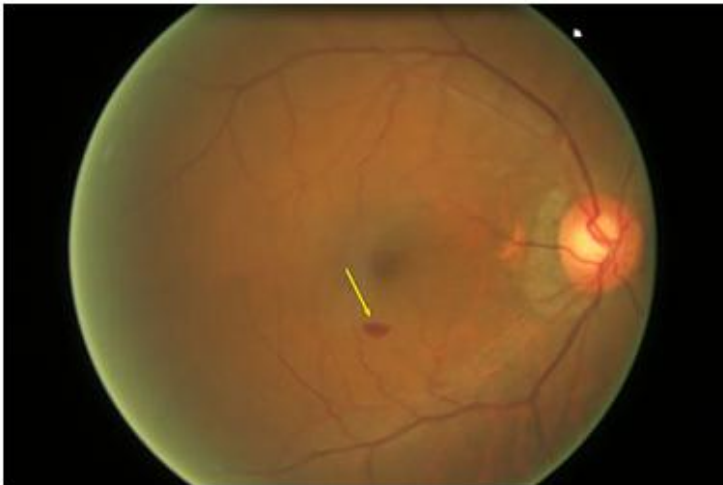Overview of the stages of diabetic retinopathy

Intraretinal haemorrhages

When the wall of a capillary or microaneurysm is sufficiently weakened, it may rupture, and cause intraretinal haemorrhage seen as a red lesion.

The haemorrhages can vary in shape. Dot haemorrhages appear as small red dots and are about the same size as large microaneurysms. They cannot always be differentiated from microaneurysms as they may look the same but vary in size.

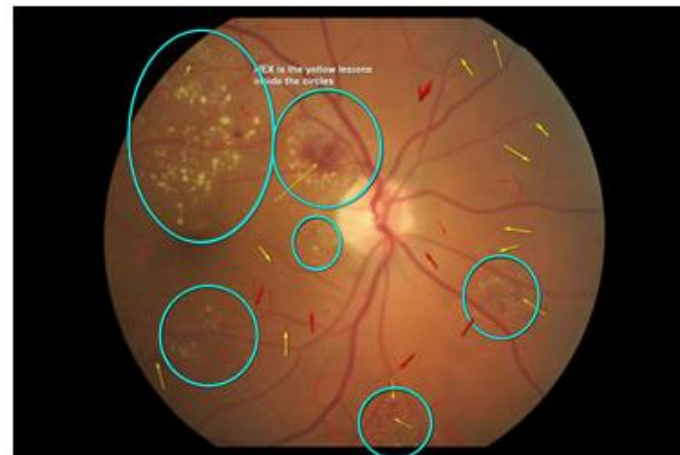Blot haemorrhages are larger lesions with round, blurred or irregular edges. These haemorrhages may look alarming, although they do not reduce vision. Flame shaped haemorrhages have the shape of a flame.



Hard exudates

Hard exudates are pale yellow, waxy looking lesions in the retina. They are lipid deposits that may accumulate in association with lipoprotein leakage from the retinal capillaries due to the breakdown of the endothelial tight junctions in microaneurysms or retinal capillaries. They may be confused with drusen (accumulations of extracellular material deeper in the retinal layers which are associated with normal ageing as well as age-related macular degeneration). However hard exudate appear more whitish and brighter than drusen in photographs.

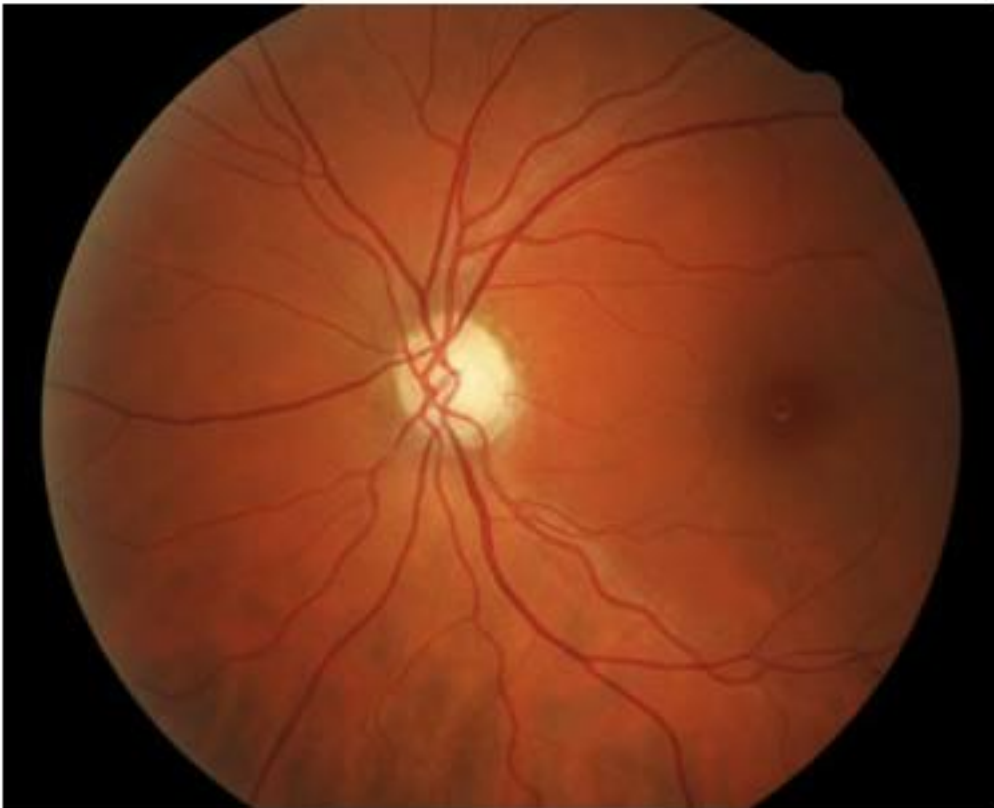Hard exudates are a surrogate marker for diabetic macular oedema and this will be discussed in the diabetic macular oedema section.



Quiz sections

Question 1

Looking at the retinal image, identify if there is pathology present, decide on the stage of retinopathy and the referral plan required.




Quiz sections

End of the Quiz

EXIT QUIZ

#	Correct Answer	Your Answer	Result	Marked Image
<u>1</u>	B. Microaneurysms C. Haemorrhages E. Hard exudates	B. Microaneurysms C. Haemorrhages E. Hard exudates	Correct	view
<u>2</u>	B. Microaneurysms C. Haemorrhages E. Hard exudates	B. Microaneurysms C. Haemorrhages E. Hard exudates	Correct	view



PEK is the yellow lesions should the circles

marked image E. Hard exudates E. Hard exudates

3 B. Microaneurysms B. Microaneurysms

Result	Marked Image
Correct	view
Correct	view

Competency Based Examination

Competency-Based Examination

The competency-based examination will determine your ability to:

- » 1. Accurately detect and grade retinopathy and macular oedema, according to the Australian National Health and Medical Research Council (NHMRC) guidelines for the management of diabetic retinopathy
- » 2. Provide appropriate referral plans, according to the NHMRC guidelines.

Visual acuity will be recorded: normal retina and low visual acuity and others with normal visual acuity and signs of diabetic retinopathy, you will need to decide on the referral required.

The competency base examination has a time limit of 1.5 hours to complete and can only be undertaken in one sitting. However, the exam can be taken again, to achieve the required pass level of 75% or greater concordance over 50 images.

Press **Start** to begin the competency based examination

Test Version

Available for Testing 19th – 26th September 2013

To receive login details email

A.Professor Robyn Tapp

robyn.tapp@unimelb.edu.au