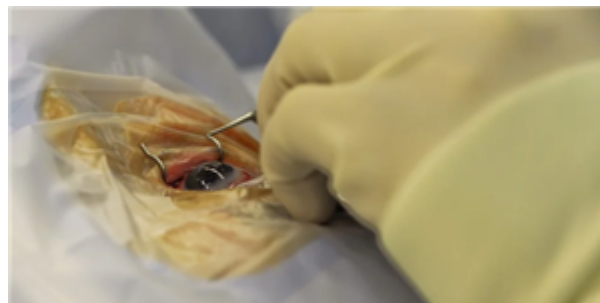


Clinical Education / News / Headlines

MAY 27, 2020

Special considerations for ophthalmic surgery during the COVID-19 pandemic



Cataract/Anterior Segment, Comprehensive Ophthalmology, Cornea/External Disease, Glaucoma, Oculoplastics/Orbit, Pediatric Ophth/Strabismus, Retina/Vitreous

+ Add to My To-Do List

Comments

Views 37616

For complete coverage of the COVID-19 pandemic, visit the Academy's resource page [Coronavirus and Eye Care](#).

As ophthalmologists resume the full spectrum of surgical practice, the Academy is offering guidance about how the COVID-19 pandemic will impact surgical decision-making, specifically around the indications for preoperative testing of patients and the use of personal protective equipment (PPE) by surgeon and staff during surgical procedures. In general, the scientific basis to estimate the risk of SARS-CoV-2 infection during most ophthalmic surgical procedures is early and evolving, and the observations and guidance here will expand and change as the science progresses.

This page is principally authored by James Chodosh, MD, MPH, with assistance from Gary N. Holland, MD, and Steven Yeh, MD.

General considerations and recommendations

Surgical masks dramatically reduce transmission of respiratory viruses, including SARS-CoV-2, from an infected individual. Every patient should be placed in a surgical mask for any ophthalmic procedure in order to prevent asymptomatic transmission to the surgeon and staff. For high volume procedures, when the number of face masks needed for patients exceeds the supply, a do-it-yourself (DIY) face mask (but not a valved respirator mask) worn by the patient is an acceptable alternative.

Topical povidone-iodine is effective against coronaviruses and should be used for surgical prep. Application of topical povidone-iodine can be repeated but should not be applied in the presence of a penetrating incision, as during intraocular surgery.

Standard surgical personal protective equipment (PPE), including a surgical mask, is sufficient for the surgeon in the majority of cases. Eye protection should be worn when possible. Note there may be instances in which eye protection is difficult or interferes with safe performance of the procedure. In such instances, close-fitting safety glasses may permit continuous wear. A sterile face shield can be placed after donning surgical loupes or an indirect ophthalmoscope. The surgeon may choose an N95 mask when specifically indicated by the condition of the patient, the prevalence of COVID-19 in their community, and/or by the type of surgery planned (see below). In many cases, the choice of mask (e.g., N95 vs. surgical mask) will be dictated by institutional protocols.

The role and interpretation of testing of patients prior to surgical procedures

No clinical suspicion for COVID-19, no known exposure, no characteristic symptoms

A role for preoperative testing of every patient remains controversial, and individual hospitals and surgery centers will typically have their own rules. Testing availability, practicality (will the test come back in time?), and accuracy all factor into decisions to test apparently healthy persons needing eye surgery. However, standard surgical PPE should suffice for this population except as below.

SARS-CoV-2 RT-PCR positive

Because COVID-19 can have lasting effects on respiratory function, if the surgery is elective, it may be better delayed for 6 weeks from the onset of symptoms. When surgery on an RT-PCR positive patient is necessary due to the potential for permanent loss of vision or loss of life if delayed, the choice of anesthesia may be impacted by the patient's overall medical condition. The surgeon and OR staff should wear N95 masks and eye protection or face shield.

SARS-CoV-2 RT PCR negative

If the test was done as part of a routine preoperative screening, in the absence of clinical suspicion of COVID-19, then surgery can proceed with PPE as below.

Serology positive

Antibodies to SARS-CoV-2 generally become apparent in the first 1 to 3 weeks days postinfection. A negative serologic test does not rule out active infection. If IgM positive/IgG negative, the patient should be considered actively infected. If IgM and IgG are both positive, infection is recent and might still be active. If IgM negative and IgG positive, the infection is in the past. However, a positive IgG test alone does not mean the patient is no longer contagious or is immune. RT-PCR testing in this scenario is indicated unless the serologic test was performed at least one month prior. Some hospitals may require 2 consecutive negative RT-PCR tests before a patient can be considered safe to operate on. For those patients with 2 negative RT-PCR tests or who are greater than 6 weeks from the onset of characteristic symptoms, standard surgical PPE should suffice.

Procedure-specific recommendations

CATARACT

Phacoemulsification

It remains unknown whether infectious SARS-CoV-2 can be present in the anterior chamber. However, the phacoemulsification procedure starts with the replacement of the aqueous humor with viscoelastic, which is then replaced by BSS irrigated from the phaco tip. Aerosolization probably occurs to some degree at the wound when the ultrasound is engaged, but it would be BSS that is aerosolized, not the patient's aqueous. Based on this logic, the risk of aerosolized virus during phacoemulsification should be very low.

YAG laser capsulotomy

It is unknown whether YAG laser can aerosolize the tear film during capsulotomy, assuming the laser is focused properly on the posterior capsule. Therefore, it would be prudent to apply a drop of 5% povidone-iodine after topical anesthesia and just before performing the procedure. The capsulotomy lens can be disinfected by gently cleaning with soap and warm water.

CORNEA/REFRACTIVE

Corneal transplantation

As of yet, there is no evidence for SARS-CoV-2 in the aqueous or vitreous humors. Corneal transplantation should not entail increased risk to the surgeon. However, open-sky phacoemulsification and anterior vitrectomy are not performed in a closed system and could theoretically aerosolize intraocular fluids. Although any aerosol generated would be diluted by BSS in the irrigation, the risk of open-sky procedures that generate an aerosol is uncertain.

Ocular surface tumors and reconstruction

The principle risk of aerosolization during ocular surface surgery would be during the use of cautery. Preoperative topical povidone-iodine as part of the surgical prep should inactivate any virus present in the tear film or on the ocular surface. Topical povidone-iodine can be used during the surgery as long as the anterior chamber is not entered and can be applied again prior to cautery. Cautery should then be performed with vigorous irrigation, so that the BSS will dilute any plume. 5% povidone-iodine can cause corneal endothelial cell damage if it enters the anterior chamber and should not be applied if there is an open surgical wound.

Laser procedures (LASIK, PRK, SMILE, PTK)

The safety of the excimer laser on the ocular surface in the setting of SARS-CoV-2 in the tear film is unknown. One prior study of the effect of excimer laser on varicella zoster virus in culture showed that infectious virus could not be cultured from the plume. In addition, current excimer instruments have aspiration systems in place with HEPA filters. At this time, the risk to the surgeon is uncertain but likely low. Femtosecond lasers that ablate tissue intrastromally should be even less likely to confer risk. Povidone-iodine prophylaxis followed by irrigation with BSS is recommended prior to beginning the procedure. It may be advisable to start the plume extractor several seconds prior to beginning the laser procedure.

Corneal cross-linking

Cross-linking is a relatively long procedure, but the UV laser used in the procedure should inactivate virus in the tear film.

GLAUCOMA

Glaucoma filtration surgery (trabeculectomy, glaucoma drainage valve implantation)

Filtration surgeries should be of low risk to the surgeon. Povidone-iodine prep should be used in every case. Use of cautery should be minimized and performed after povidone-iodine and with vigorous irrigation.

Minimally invasive glaucoma surgery (MIGS)

MIGS should be of low risk to the surgeon. Povidone-iodine prep should be used in every case. Use of cautery should be minimized and performed after povidone-iodine prep with vigorous irrigation.

Laser iridotomy

It is not known to what degree the argon or YAG laser can generate an aerosol when the laser is focused on the iris. Therefore, it would be prudent to apply a drop of 5% povidone-iodine after topical anesthesia and just before performing the procedure. The capsulotomy lens can be disinfected by gently cleaning with soap and warm water.

Cyclophotoablation procedures

Topical povidone-iodine can be used prior to and during the procedure.

RETINA

Pars plana vitrectomy (PPV) and other posterior segment procedures

Evidence for SARS-CoV-2 in the vitreous humor is currently lacking. The virus can be neuroinvasive, so intraocular virus is theoretically possible. However, PPV is most commonly performed with a closed surgical system with valved trocar cannulas. During phacoemulsification, the entire aqueous volume is replaced by viscoelastic, but this does not occur during PPV. During PPV, aerosolization of liquid vitreous is theoretically possible. However, with valved trocar cannula systems, any aerosols would be expected to be contained within the eye. These factors suggest that the PPV procedure carries a low risk of viral transmission to the surgeon and staff. Laser photocoagulation is discussed below. Use of external cautery should be minimized and performed with irrigation to dilute any aerosol with BSS. Standard surgical PPE is sufficient.

Intravitreal injections

Assuming povidone-iodine is used as a surgical prep, there is no additional risk of transmission from the ocular surface. However, an N95 mask can be considered for surgeons who place themselves very close to the patient while performing injections, in order to minimize potential spread from the patient's exhaled breath around the surgical mask.

Argon laser procedures (PRP)

Topical povidone-iodine can be used prior to the procedure. If the laser treatment is prolonged, additional instillation of povidone-iodine can be considered after treatment with a topical anesthetic. Care should be taken given the risk of corneal epitheliopathy with repeat povidone-iodine treatment. Special attention to disinfection of instruments (i.e. scleral depressor, indirect ophthalmoscope, condensing lens) are recommended.

OCULOFACIAL PLASTICS

Repair of canalicular laceration, probing of nasolacrimal duct

Dacryocystorhinostomy (DCR)

Repair of eyelid/face tissues or fractures

Orbital tumors**Anophthalmic socket surgery; conjunctival-Mullerectomy ptosis repair****Procedures involving mucous membranes: Nasal endoscopy; harvesting mucosal grafts from mouth and nose; lip filler**

Generation of aerosols is likely for all of these procedures. Unless the patient is tested and RT-PCR negative for SARS-CoV-2 just prior to surgery, an N95 mask and face shield are recommended for the surgeon and staff.

PEDIATRIC OPHTHALMOLOGY**Strabismus/muscle surgery**

The major concern with strabismus surgery is associated with cautery. Preoperative topical povidone-iodine as part of the surgical prep should inactivate any virus present in the tear film or on the ocular surface. Topical povidone-iodine can be used during the surgery as long as the anterior chamber is not entered and can be applied again prior to cautery. Cautery should then be performed with vigorous irrigation, so that the BSS would dilute any plume. 5% povidone-iodine can cause corneal endothelial cell damage if it enters the anterior chamber and should not be applied if there is an open surgical wound.

Nasolacrimal duct surgery

Unless the patient has been tested and is RT-PCR negative for SARS-CoV-2, an N95 mask and face shield are recommended for the surgeon and operating room staff.

James Chodosh, MD, MPH, is the Edith Ives Cogan Professor of Ophthalmology at Harvard Medical School's Department of Ophthalmology, a member of Harvard's PhD program in virology and an expert in cornea and external disease working at the Massachusetts Eye and Ear.

Gary N. Holland, MD, is the Jack H. Skirball Professor of Ocular Inflammatory Diseases, director of the Ocular Inflammatory Disease Center, and a member of the cornea/external disease and uveitis divisions at the Jules Stein Eye Institute, David Geffen School of Medicine at UCLA.

Steven Yeh, MD, is the M. Louise Simpson Associate Professor of Ophthalmology, a member of the uveitis and vitreoretinal surgery divisions at the Emory Eye Center, and a faculty fellow of the Emory Global Health Institute.

AAO.org offers commenting on articles for members of the American Academy of Ophthalmology. Read our commenting guidelines before participating. Comments are visible only to logged-in members. Your colleagues expect that you will treat this space as private and that you will not share their comments through screenshots or other methods of reproduction. The opinions expressed represent the views of the individual participants, not the position of the Academy.

Get a weekly snapshot of popular topics: Subscribe to the Conversations newsletter

Related

SARS-CoV-2 viral material from asymptomatic carriers found on ophthalmology examination room surfaces *Editors' Choice*

Hydroxychloroquine shows no benefits for postexposure COVID-19 prophylaxis *Editors' Choice*

Management of Anomalous Head Position in Nystagmus *Clinical Video*

Week in review: Optical illusion, eye mask, crocodile tears *Headline*

Topical therapy appears effective for closing secondary macular holes *Editors' Choice*

Most Commented

1. Help Us Stop Rubber Bullets Before They Blind More People
2. How to Take Retinal Images with a Smartphone
3. Infection Control Measures during Simulated Slit Lamp Examination

Most Viewed

1. Coding for Phone Calls, Internet and Telehealth Consultations
2. FDA issues alert on intraocular compounded moxifloxacin
3. Academy, Surgical Care Coalition Ramp Up Pressure to Stop Drastic Medicare Fee Cuts to Surgical, Physician Services

[Contact Us](#)

[About the Academy](#)

[Jobs at the Academy](#)

[Financial Relationships with Industry](#)

[Medical Disclaimer](#)

[Privacy Policy](#)

[Terms of Service](#)

[Help](#)

[For Advertisers](#)

[For Media](#)

[Ophthalmology Job Center](#)

OUR SITES

[EyeWiki](#)

[International Society of Refractive Surgery](#)

FOLLOW THE ACADEMY

Medical Professionals



Public & Patients



Museum of the Eye



© American Academy of Ophthalmology 2020

Comments for this thread are now closed



0 Comments

Academy Conversations

Disqus' Privacy Policy

Lila Puri ▾

Recommend 3

Tweet

Share

Sort by Oldest ▾

This discussion has been closed.

Subscribe Do Not Sell My Data

Puri, Lila Raj ▾

My Account

My Meetings

My Education/CME

My To-Do List

My Browsing History

My Online Products

Log Out

Select Language ▾

Powered by **Google Translate**